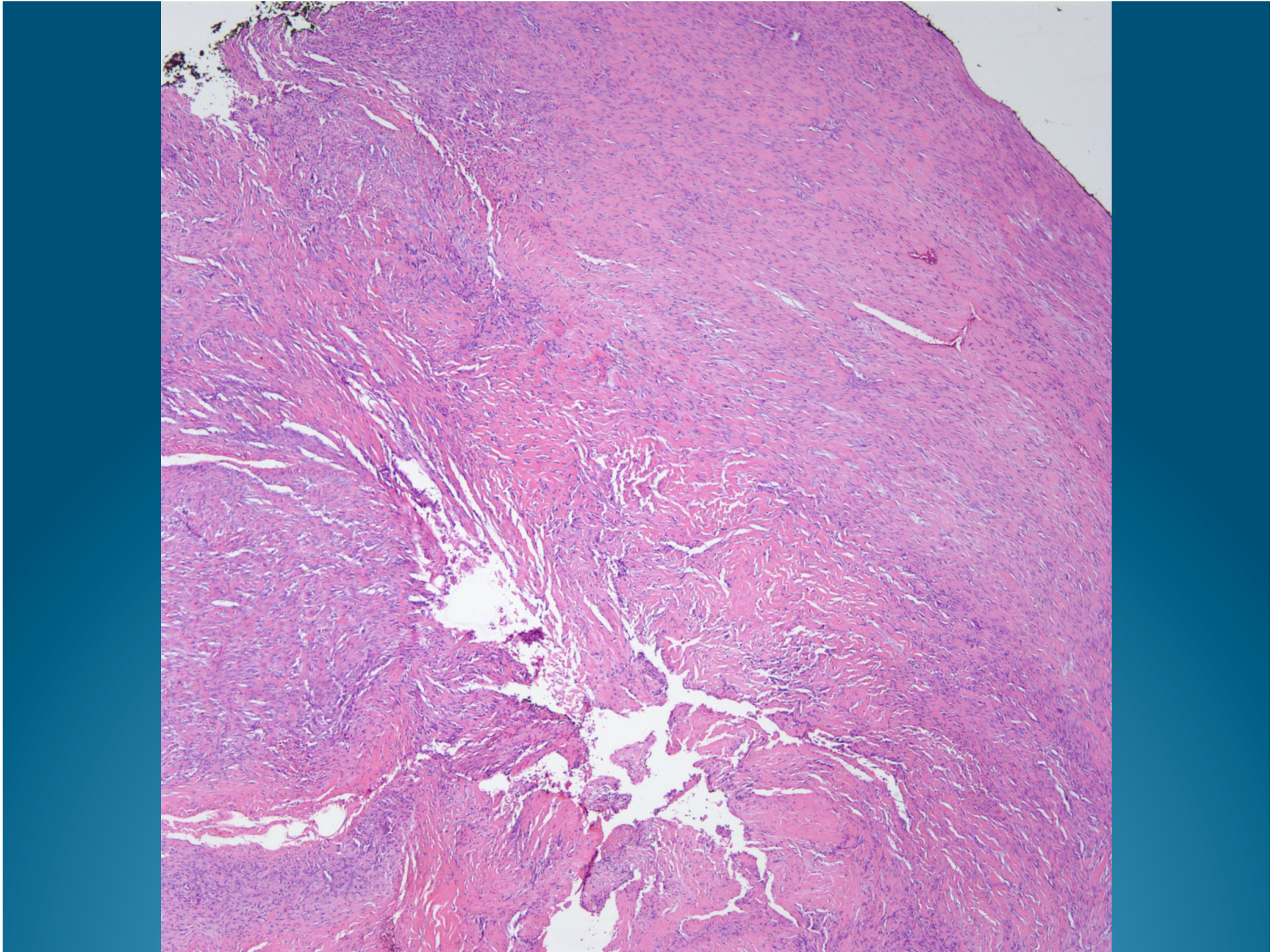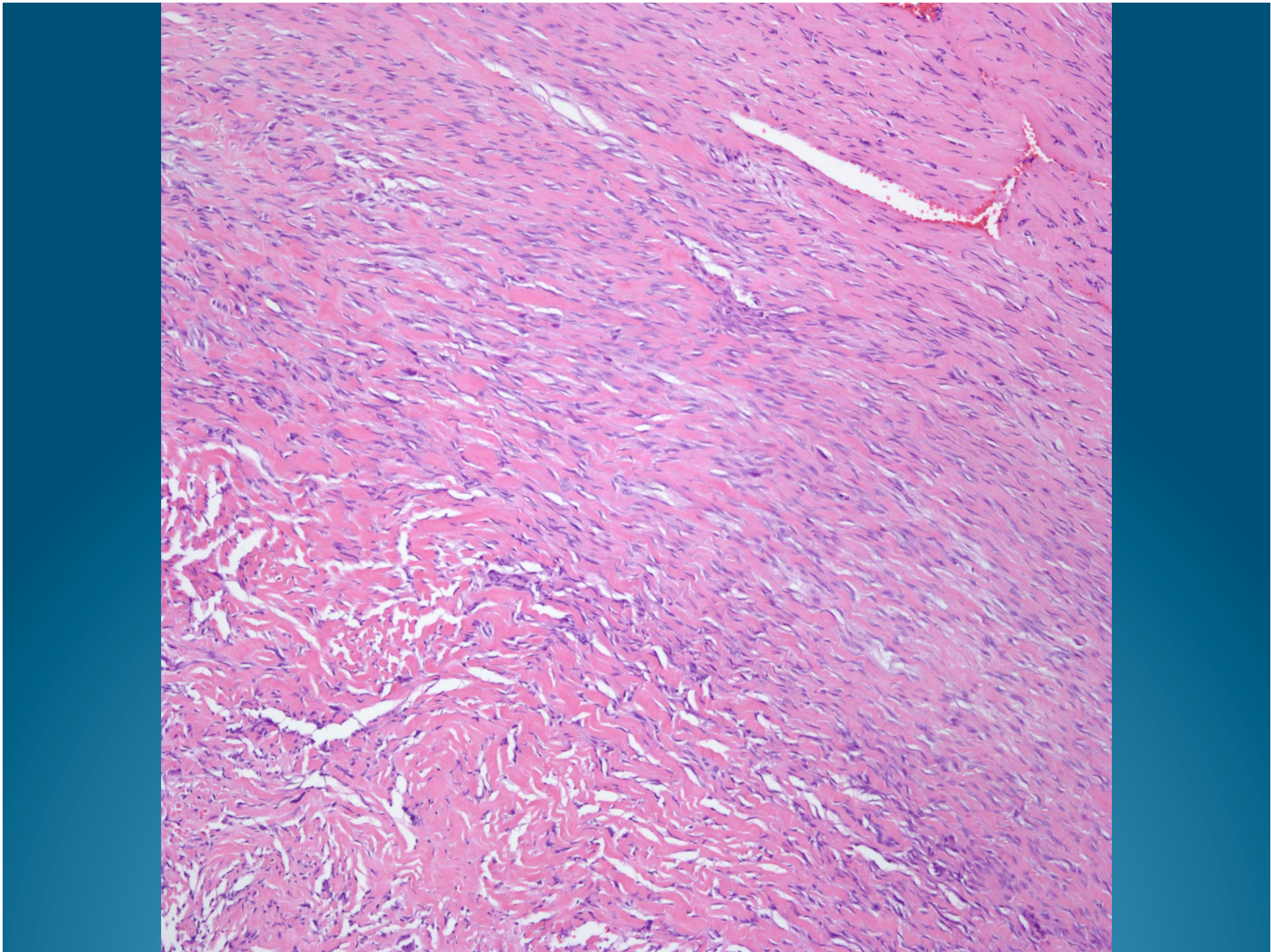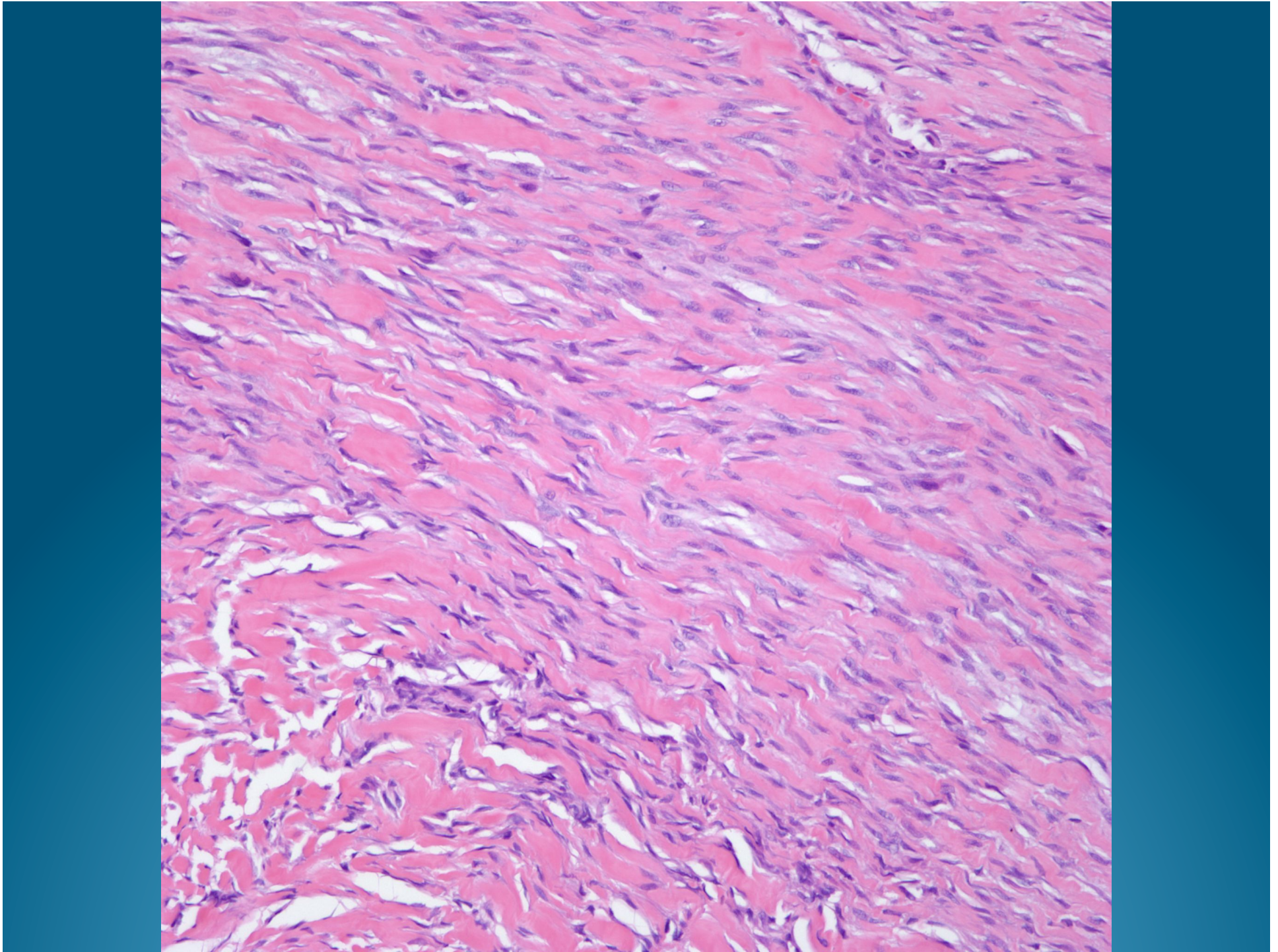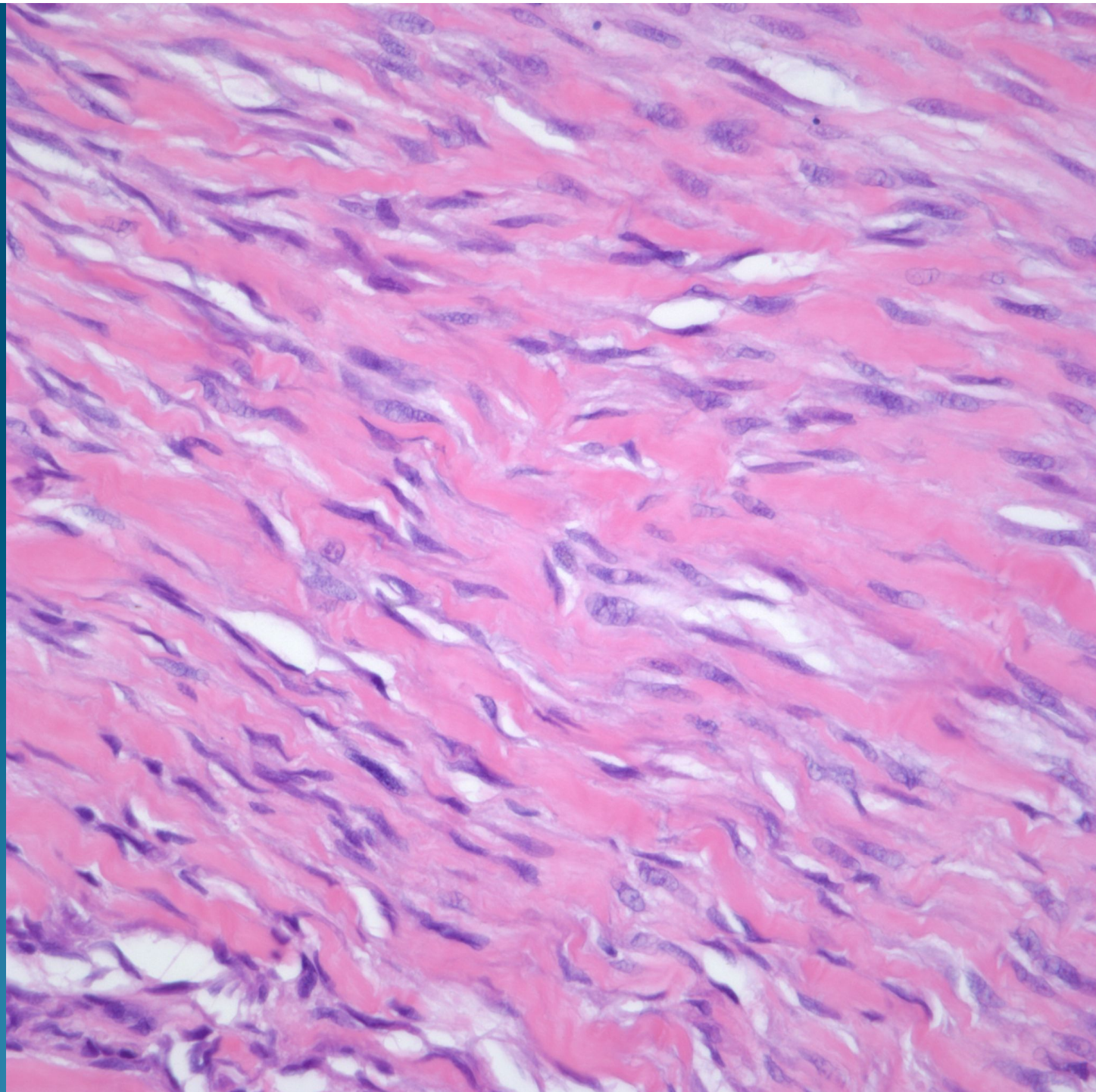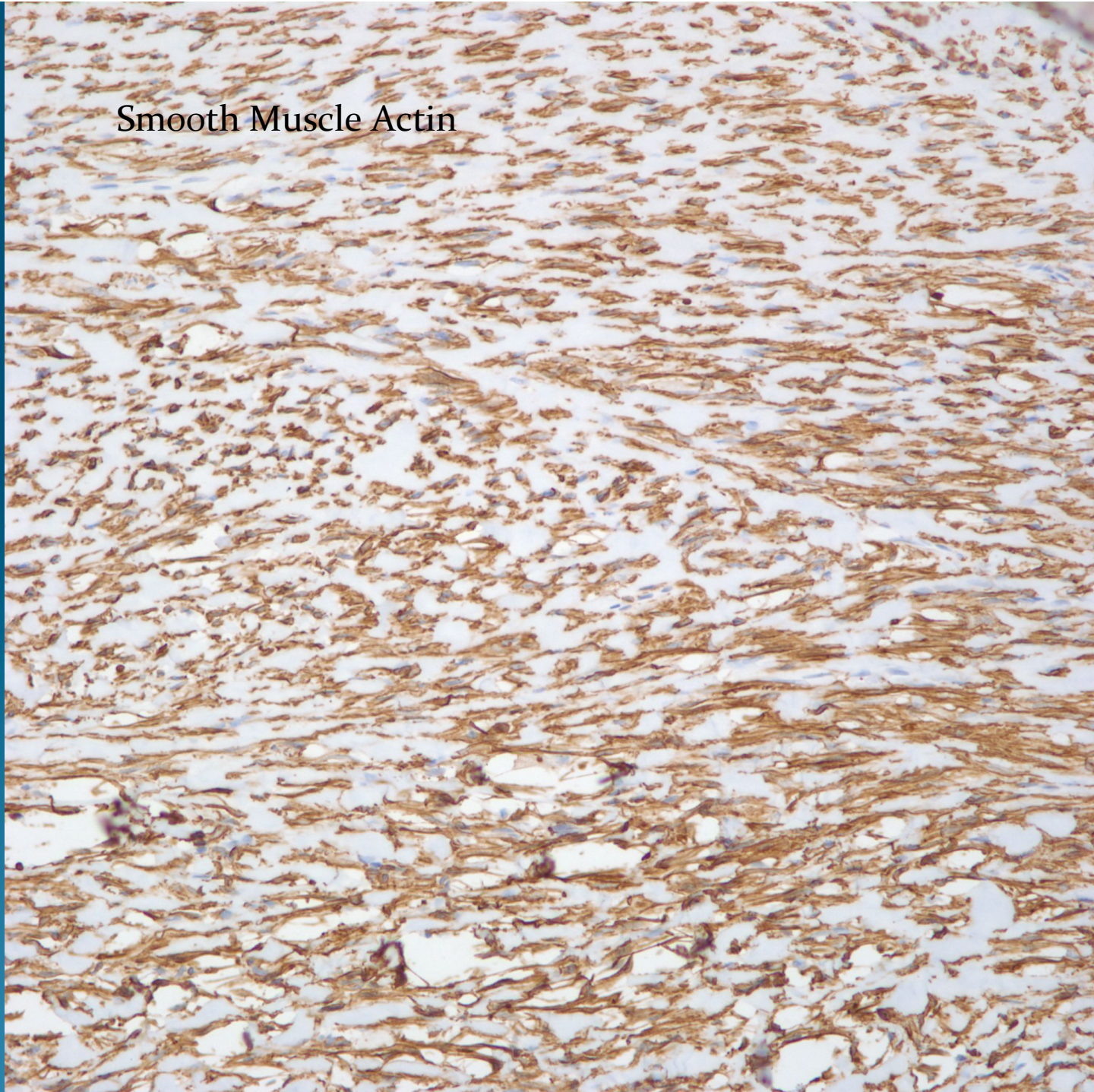
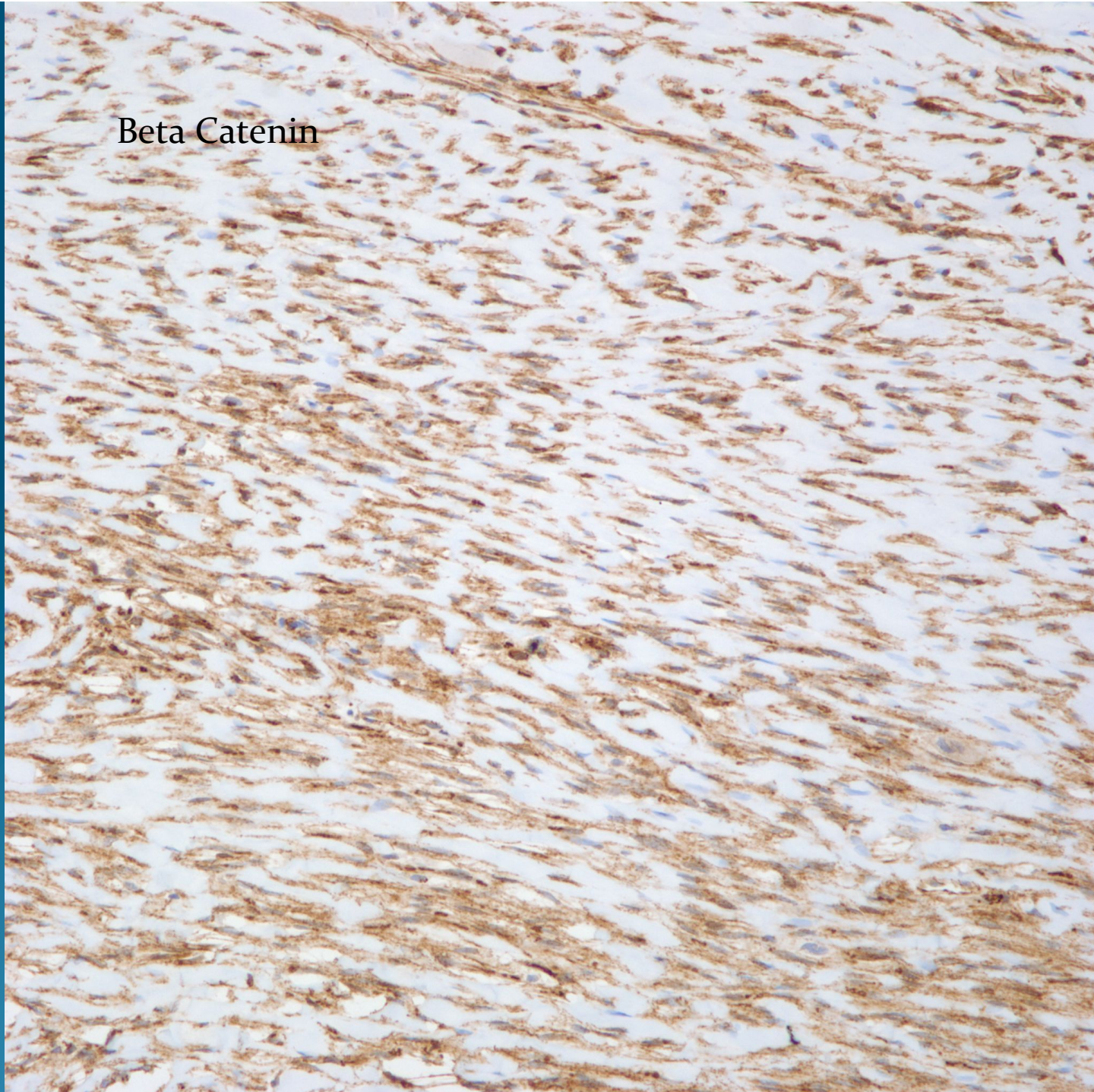


Smooth Muscle Actin



Beta Catenin



What is the best diagnosis?

- A. Fibrosarcoma
- B. Schwannoma
- C. Dermatofibroma
- D. Nodular fasciitis
- E. Fibromatosis

Fibromatosis

Notes

- This was a soft tissue thigh mass that arose over a span of 4 months in a 17 year old male with a history of possible trauma to the area.
- Although the clinical history suggested nodular fasciitis, this tumor lacked the characteristic histopathology.
- The positive staining for beta-catenin is supportive of fibromatosis. Note, that both fibromatosis and nodular fasciitis may be smooth muscle actin positive.

Diffuse
Infiltrate
Of bland
Spindle
cells

Sclerotic
background

Minimal
To absent
Mitotic
figures

